

RESEARCH

Open Access



Correlation of sonographic with intraoperative findings in laparoscopic managed ectopic pregnancies, a 10-year synopsis: a retrospective observational study

Steve Kyende Mutiso^{1*}

Abstract

Background Ectopic pregnancies (EP) are a common pregnancy complication that's associated with significant morbidity and rarely mortality if not managed properly. Ultrasound examination forms the cornerstone of diagnosis of EP with some sonographic features occasionally not correlating with intraoperative findings. We set out to conduct an audit of EP managed surgically at our hospital for a 10-year period and discern the correlation and prediction of sonographic findings to intraoperative findings.

Methods This study was designed as a Retrospective Observational Study based at the Aga Khan University Hospital (AKUH). Study population was all women admitted to AKUH with a diagnosis of ectopic pregnancy that was surgically managed between the period of January 1st 2011 to December 31st 2020. Analysis of data was done against a pre-set checklist. Descriptive statistics for continuous variables was calculated and tabulated in graphs and tables. SPSS version 22 was used for analysis of data.

Results A total of 337 patients in this study had ultrasound findings. 99.7% ($n = 336$) of these patients had an intraoperatively confirmed EP. The commonest ultrasound finding was an adnexal mass in 97.1% ($n = 309$) of patients. These were confirmed surgically in 290 patients at the following locations: 76.6% ($n = 222$) were ampullary in location; 10.7% ($n = 31$) were fimbrial in location; 8.6% ($n = 25$) were isthmic in location; 2.4% ($n = 7$) were interstitial in location; 1% ($n = 3$) were abdominal in location; while 0.3% were located in the ovary ($n = 1$) or round ligament ($n = 1$) each. Interstitial EP on ultrasound were all (100%) confirmed in the same location intraoperatively, with ampullary EP also correlating fairly well with intraoperative location (75%). The distribution of location in the minor hemoperitoneum (HP) versus major HP groups were similar except for interstitial EP that increased from 1.4% in the minor HP group to 9.5% in the major HP group.

Conclusion In conclusion, ultrasonography still represents the best imaging modality for EP. The most common finding is usually an adnexal mass with no specific location. Most (99.7%) of the patients with this sonographic finding usually have a confirmed EP. Interstitial EP are the most well localized with ultrasound followed by ampullary EP.

*Correspondence:
Steve Kyende Mutiso
steve.mutiso@aku.edu

Full list of author information is available at the end of the article



© The Author(s) 2024. **Open Access** This article is licensed under a Creative Commons Attribution 4.0 International License, which permits use, sharing, adaptation, distribution and reproduction in any medium or format, as long as you give appropriate credit to the original author(s) and the source, provide a link to the Creative Commons licence, and indicate if changes were made. The images or other third party material in this article are included in the article's Creative Commons licence, unless indicated otherwise in a credit line to the material. If material is not included in the article's Creative Commons licence and your intended use is not permitted by statutory regulation or exceeds the permitted use, you will need to obtain permission directly from the copyright holder. To view a copy of this licence, visit <http://creativecommons.org/licenses/by/4.0/>. The Creative Commons Public Domain Dedication waiver (<http://creativecommons.org/publicdomain/zero/1.0/>) applies to the data made available in this article, unless otherwise stated in a credit line to the data.

Furthermore, the presence of major (> 500mls) hemoperitoneum may act as an adjunct for diagnosis of an interstitial EP.

Keywords Ectopic pregnancy, Surgery, Ultrasound, Location, Correlation

Background

Ectopic Pregnancies (EP) are a common and significant cause of pregnancy related morbidity [1]. Ultrasound examination forms the cornerstone of diagnosis of EP with combination with clinical features and laboratory findings [2]. In this combination, the specificity of diagnosis EP is above 95% [3].

However, sonographic features may not correlate with intraoperative findings in about 10% of patients with some diagnostic laparoscopies for EP being negative [4]. Moreover, other sonographic findings such as the location or size of the EP may not correlate to intraoperative findings leading to a change of surgical strategy intraoperatively [5]. They also may not correlate well to other findings such as the volume of hemoperitoneum and even presence of an EP [4, 6].

We set out to conduct an audit of EP managed surgically at our hospital for a 10-year period and discern the correlation and prediction of sonographic findings to intraoperative findings.

Methods

Study setting and design

This study was designed as a Retrospective Observational study based at the Aga Khan University Hospital (AKUH). Study population was all women admitted to AKUH with a diagnosis of ectopic pregnancy that was surgically managed between the period of January 1st 2011 to December 31st 2020. Data was collected from clinical records during admission at AKUH. All patients were subjected to a full history taking and physical examination and laboratory tests including complete blood count, qualitative or quantitative Beta-human chorionic gonadotrophin (HCG), transvaginal and/or transabdominal ultrasound with determination of adnexal mass if present and presence and quantification of intraperitoneal haemorrhage. This was as per the management protocols at AKUH.

Study procedures

Selection criteria

Inclusion Criteria will be all women diagnosed with ectopic pregnancies that were surgically managed at the AKUH that fulfilled the criteria for surgical management in accordance to the AKUH Early Pregnancy Bleeding protocol.

Exclusion criteria will be:

- Patients not treated at the Aga Khan University Hospital.
- Patients treated with any other methods i.e. conservative or medical.
- Patients with a heterotopic pregnancy.
- Patients files with missing data.

Study tools

A data collection tool was designed incorporating pre-operative ultrasound findings, intraoperative findings, postoperative complications and costs attributed to the surgery. Standards of best practice is to be in accordance to the Royal College of Obstetricians and Gynaecologists Green Top Guideline, Number 21 [7].

Data analysis and management

Analysis of data was done against a pre-set checklist. Descriptive statistics for continuous variables was calculated and tabulated in graphs and tables. These included: location of EP on ultrasound; intraoperative findings & volume of hemoperitoneum. Linear regression was done to ascertain whether the size of mass identified correlated with the volume of hemoperitoneum with the p value set at 0.005.

Statistical Package for Social Sciences (SPSS) version 22 was used for analysis of data.

The data collected was de-identified to maintain privacy and confidentiality. Collected data did not include patients name to safeguard patients' privacy. The files were accessed at medical records and did not leave the custody of the medical records office. Data was collected using a data collection tool designed from the database file. Data was then entered directly into the database document created for use in this audit. The primary investigator (PI) was the sole custodian of this document and which was submitted to the research office at the end of the audit for archiving as with other studies. The hard copies of the data collection tools were also submitted to the research office for archiving. A back up copy of the document was kept on an online data cloud that will be password protected and accessible to the PI.

Results

During the study period (2011–2020), we recorded 347 cases of surgically managed ectopic pregnancies. A total of 337 patient had sonographic findings which represents 97.1% of the total sample. An adnexal mass was the commonest sonographic finding on ultrasound with 91.7%

($n=309$) of the scans concluding this finding. Significant free fluid in the Pouch of Douglas (POD), defined as fluid that was more than 30 cubic centimetres in volume, was the second most common finding in 4.7% of the ultrasound scans ($n=16$). The other findings included: an ampullary mass in 1.2% ($n=4$); ovarian and interstitial mass each in 0.9% ($n=3$) and no mass was identified in 0.6% ($n=2$) of the patients. The patients with no mass on ultrasound were labelled as pregnancy of unknown location (PUL). These finds are shown in Fig. 1 below.

A total of 336 patients had a confirmed ectopic pregnancy during surgery. A total of 11 patients (3.2%) did not have any discernible EP during surgery. In the patients with sonographic findings ($n=337$), only 1 patient had a negative laparoscopy with no EP identified. This patient had a corpus luteum cyst on the side of the suspected EP and this could have led to the wrong diagnosis of this adnexal mass. This represents less than 0.3% of patients in this study.

On analysis regarding the sonographic location corresponding with the intraoperative location, a total of 4 patients had a sonographic location of an ampullary EP, 75% [3] of these patients confirmed this location on surgery. A total of 3 patients had a suspicion of an ovarian EP on ultrasound. However, none (0%; $n=0$) of these patients had an ovarian EP but 2 (67%) had an ampullary EP while 1 (33%) had an interstitial EP. The 3 patients who had a sonographic finding of an interstitial EP all had interstitial EP (100%).

A total of 309 Patients had a sonographic finding of an adnexal mass, 290 of these were confirmed surgically at the following locations: 76.6% ($n=222$) were ampullary in location; 10.7% ($n=31$) were fimbrial in location; 8.6% ($n=25$) were isthmic in location; 2.4% ($n=7$) were interstitial in location; 1% ($n=3$) were abdominal in location; while 0.3% were located in the ovary ($n=1$) or round ligament each ($n=1$). This data is shown in Fig. 2. 15

patients had a finding of free fluid in the POD on ultrasound that on surgery were redistributed as 67% ($n=10$) were ampullary, 20% ($n=3$) were fimbrial and 13% ($n=2$) were interstitial (cornual) in location. The one patient who had a PUL on ultrasound had an ampullary EP.

In the analysis of location of EP and whether it could impact on the volume of hemoperitoneum, we subdivided the data into minor hemoperitoneum (<500mls) or major hemoperitoneum (>500mls). The patients with minor hemoperitoneum were 213 in number; 76.5% ($n=163$) of these patients had an ampullary EP. 8.4% ($n=18$) had an isthmic EP, 12.2% ($n=26$) had a fimbrial EP, 1.4% ($n=3$) had a corneal EP, 1% ($n=2$) had an abdominal EP, 0.5% ($n=1$) had a round ligament EP and there were no ovarian EP in this group. This information is displayed in Fig. 3.

The patients with major hemoperitoneum were 105 in number; 71.4% ($n=75$) of these patients had an ampullary EP. 7.6% ($n=8$) had an isthmic EP, 10.5% ($n=11$) had a fimbrial EP, 1% ($n=1$) had an ovarian EP and 9.5% ($n=10$) had a interstitial EP and there were no abdominal or round ligament EP in this group. The major significant difference was that corneal EP had a significantly larger proportion of patients in the major hemoperitoneum group compared to the minor hemoperitoneum group (9.5% versus 1.4%). This data is shown in Fig. 4.

Presence of a mass on ultrasound almost invariably corresponded with the presence of an EP at surgery. At total of 139 patient had a mass visualized on ultrasound examination and 97.8% ($n=136$) of these patients had a confirmed EP at surgery. All patients ($n=63$; 100%) with a mass size above 38 mm had an EP at surgery.

We further analysed whether the diameter of the EP mass seen on scan could predict the volume of hemoperitoneum and there was no significant correlation ($p=0.995$, Confidence Interval -3.0 to 5.584). This meant

SONOGRAPHIC FINDINGS

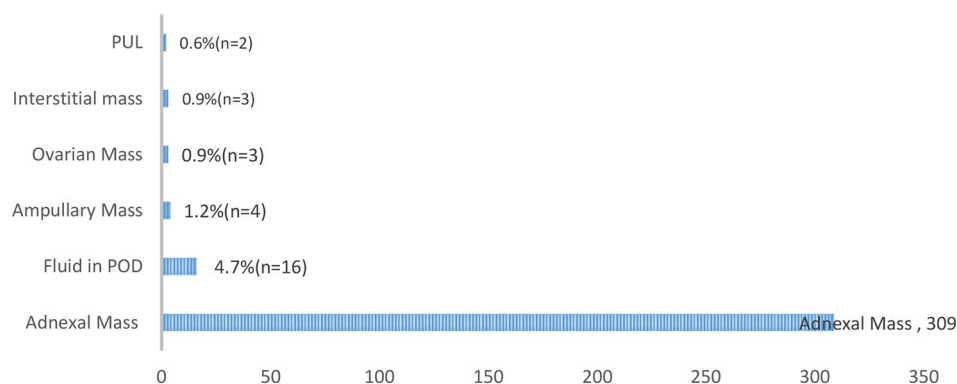


Fig. 1 Distribution of sonographic findings in patients with surgically managed EP

DISTRIBUTION OF ADNEXAL MASSES ON ULTRASOUND AS SEEN

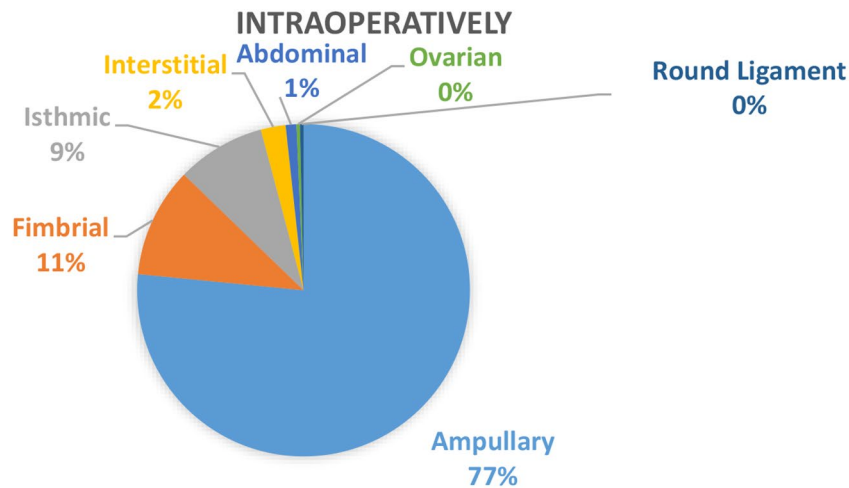


Fig. 2 Distribution of Adnexal Masses on Ultrasound with their intraoperative location

DISTRIBUTION OF PATIENTS WITH MINOR HEMOPERITONEUM BY LOCATION

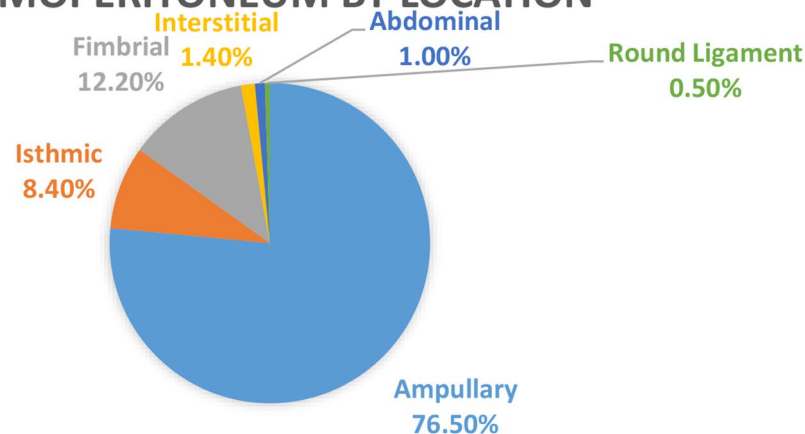


Fig. 3 Distribution of patients with minor hemoperitoneum by location

that increasing size of mass on ultrasound did not predict an increased volume of hemoperitoneum.

Discussion

EP are an important cause of pregnancy related morbidity and mortality [8]. Their early diagnosis is key with ultrasound examination being central to the investigations required for this to be achieved [5]. We assessed the correlation of sonographic with intraoperative findings among patients with laparoscopically managed EP at a tertiary referral centre.

An adnexal mass was the commonest finding in the present study with 97.1% of the ultrasounds done having this finding. This is in keeping with previous studies that cite this as the major finding in most EP [9]. An adnexal

mass with a positive pregnancy test without an intrauterine pregnancy is usually diagnostic of an EP [9]. This is usually the earliest sign even prior to development of a hemoperitoneum [10]. An adnexal mass is seen in around 89–100% of endovaginal ultrasounds done for EP [4]. An adnexal mass can be attributed to the actual pregnancy or an associated hematoma from haemorrhage [9]. In EP that occur in other sites, different ultrasonographic identifiers have been described in literature [11]. Interstitial EP usually have an eccentric location proximal to the uterine cornua with an echogenic line (interstitial line) that may extend from the endometrium to the interstitial mass [12]. Ovarian EP are difficult to identify unless a gestational sac with an embryo surrounded by ovarian tissue is identified [13]. Ovarian EP have also being

DISTRIBUTION OF PATIENTS WITH MAJOR HEMOPERITONEUM BY LOCATION

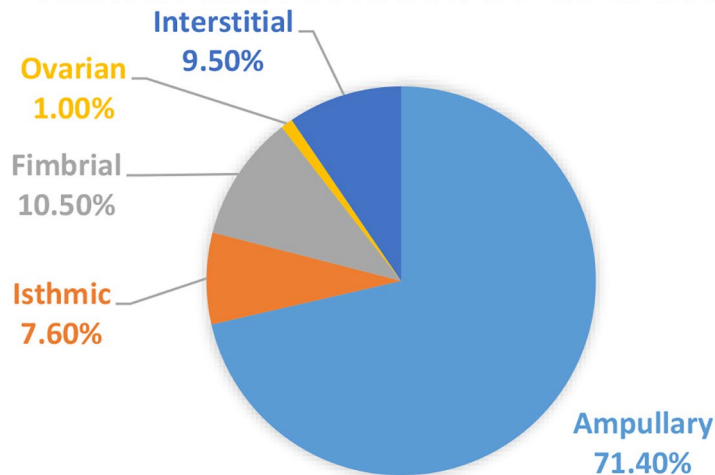


Fig. 4 Distribution of patients with major hemoperitoneum by location

described using the Spiegelberg criteria. These include: a normal uninvolved ipsilateral fallopian tube; the gestational sac being in the normal position of the ovary & the ovary and the gestational sac are connected to the uterus via the ovarian ligament [13]. A cesarean scar pregnancy will be sonographically identified by seeing a pregnancy that's implanted in a prior cesarean scar location usually in the low anterior position closer to the cervix than the uterine fundus [14]. Abdominal pregnancies are usually identified by either a gestational sac or a fetus or placental tissue that's outside the uterus with no surrounding myometrium between it and other pelvic organs like the urinary bladder [7]. Endovaginal ultrasound is better than transabdominal ultrasound in detecting an EP [15].

337 patients in the present study had a sonographic finding expected with an EP. Only 1 patient had a negative laparoscopy representing a detection rate of 99.7%. This high detection rate is in keeping with previous studies with the ultrasound performing better than most imaging modalities [4, 5, 9]. The use of endovaginal sonography almost virtually eliminates the possibility of an EP being missed [15].

In correlating the sonographic location to the intraoperative one, most patients (91.6%) just had a finding of an adnexal mass with no specific location of the EP. This is an expected trend since ultrasound rarely identifies the specific location of an EP with the finding of an adnexal mass being the most common [9]. In terms of specific location, 75% of patients an ampullary location on ultrasound were confirmed intraoperatively. This is in keeping with studies on the sensitivity of ultrasound localizing ampullary EP pregnancies [11, 16]. This is based on the

facts that since this is the most common location of EP then a large proportion of ultrasounds may get this location right by chance. However, none of the patients with an ovarian EP were confirmed at that location intraoperatively. This is a usual phenomenon since most of the ovarian EP rarely appear as EP on ultrasound [17]. They are more often identified as ovarian cysts since majority rarely develop a sonographically discernible gestational sac [17]. All patients who had interstitial EP on scan were confirmed intraoperatively. This high pick up rate is in keeping with previous studies on pickup rate of interstitial EP [10, 12]. This is attributed to the fact that Interstitial EP have specific findings on ultrasound among which the interstitial line finding may be the most sensitive (80%) and specific (98%) of these findings [12].

The distribution of the location of EP in the present study was as follows: ampullary 77%; fimbrial 11%; isthmic 9%, interstitial 2% and abdominal 1%. Ovarian or round ligament EP were the rarest representing only 0.3% each. This trend is in keeping with the natural distribution of EP that expected [18]. This trend is anticipated due to the physiology of fertilization and hence decreasing incidence from that site proximally or distally [9]. However, the present study had a lower rate (0.3%) of ovarian EP than expected (3.2%). This may be attributed to the fact that these are random EP in occurrence that may or may not happen as common in a given population [11].

We further analysed whether the volume of hemoperitoneum (HP) had any particular trend with regards to the location of EP. In the regards we classified them under major or minor haemorrhage with the

cut off between the two being 500 millilitres(mls) of HP. The most significant disparity occurred in the interstitial EP which only accounted for 1.4% of the patients in the minor HP group compared with 9.5% in the major HP group. This is in keeping with studies of interstitial EP due to the fact that most of them are usually ruptured at diagnosis and hence may have a higher volume of HP expected [19]. In patients with equivocal findings of an interstitial EP, identification of major HP may be a useful adjunct to confirming its location.

Study limitations

This was a retrospective chart audit; a prospective study would have yielded a better data set. However, due to the nature of the standardized practice at our university hospital, the data set was consistently complete.

Conclusion

In conclusion, ultrasonography still represents the best imaging modality for EP. The most common finding is usually an adnexal mass with no specific location. Most (99.7%) of the patients with this sonographic finding usually have a confirmed EP. Interstitial EP are the most well localized with ultrasound followed by ampullary EP. Furthermore, the presence of major (>500mls) hemoperitoneum may act as an adjunct for diagnosis of an interstitial EP.

Abbreviations

AKUH	Aga Khan University Hospital
EP	Ectopic Pregnancies
HCG	Human Chorionic Gonadotrophin
HP	Hemoperitoneum
MLS	Millilitres
SPSS	Statistical Package for Social Sciences

Acknowledgements

The faculty members, and my colleagues for their invaluable input and for being a great source of support to me during this study.

Author contributions

SKM - Conception and design, Acquisition of data, Analysis and interpretation of data. Drafting the article, Critical revision of the article and final approval of the version to be published.

Funding

This study was not funded.

Data availability

The materials used during the current study are available from the corresponding author on reasonable request.

Declarations

Ethics approval and consent to participate

Ethics approval was obtained from the Aga Khan University, Nairobi Institutional Ethics Review Committee. The need for informed consent was waived by the Aga Khan University, Nairobi Institutional Ethics Review Committee.

Consent for publication

Not applicable.

Competing interests

The authors declare no competing interests.

Author details

¹Department of Obstetrics and Gynaecology, Aga-Khan University, P.O. Box 30270-00100, Nairobi, Kenya

Received: 29 November 2023 / Accepted: 24 March 2024

Published online: 20 April 2024

References

1. Creanga AA, Shapiro-Mendoza CK, Bish CL, Zane S, Berg CJ, Callaghan WM. Trends in ectopic pregnancy mortality in the United States: 1980–2007. *Obstet Gynecol.* 2011;117(4):837–43.
2. Webster K, Eadon H, Fishburn S, Kumar G. Ectopic pregnancy and miscarriage: diagnosis and initial management: summary of updated NICE guidance. *BMJ (Clinical Res ed).* 2019;367:l6283.
3. Condous G, Kirk E, Lu C, Van Huffel S, Gevaert O, De Moor B, et al. Diagnostic accuracy of varying discriminatory zones for the prediction of ectopic pregnancy in women with a pregnancy of unknown location. *Ultrasound Obstet Gynecology: Official J Int Soc Ultrasound Obstet Gynecol.* 2005;26(7):770–5.
4. Atri M, Leduc C, Gillett P, Bret PM, Reinhold C, Kintzen G, et al. Role of endovaginal sonography in the diagnosis and management of ectopic pregnancy. *Radiographics: Rev Publication Radiological Soc North Am Inc.* 1996;16(4):755–74. discussion 75.
5. Dogra V, Paspulati RM, Bhatt S. First trimester bleeding evaluation. *Ultrasound Q.* 2005;21(2):69–85. quiz 149–50, 53–4.
6. Cirillo F, Paladino I, Ronchetti C, Busnelli A, Morengi E, Grilli L, et al. Ectopic pregnancy risk factors in infertile patients: a 10-year single center experience. *Sci Rep.* 2022;12(1):20473.
7. Allibone GW, Fagan CJ, Porter SC. The sonographic features of intra-abdominal pregnancy. *J Clin Ultrasound: JCU.* 1981;9(7):383–7.
8. Hoover KW, Tao G, Kent CK. Trends in the diagnosis and treatment of ectopic pregnancy in the United States. *Obstet Gynecol.* 2010;115(3):495–502.
9. Dialani V, Levine D. Ectopic pregnancy: a review. *Ultrasound Q.* 2004;20(3):105–17.
10. Jurkovic D, Mavrelos D. Catch me if you scan: ultrasound diagnosis of ectopic pregnancy. *Ultrasound in obstetrics & gynecology. Official J Int Soc Ultrasound Obstet Gynecol.* 2007;30(1):1–7.
11. Dibble EH, Lourenco AP. Imaging unusual pregnancy implantations: rare ectopic pregnancies and more. *AJR Am J Roentgenol.* 2016;207(6):1380–92.
12. Ackerman TE, Levi CS, Dashofsky SM, Holt SC, Lindsay DJ. Interstitial line: sonographic finding in interstitial (cornual) ectopic pregnancy. *Radiology.* 1993;189(1):83–7.
13. Odejimi F, Rizzuto MI, Macrae R, Olowu O, Hussain M. Diagnosis and laparoscopic management of 12 consecutive cases of ovarian pregnancy and review of literature. *J Minim Invasive Gynecol.* 2009;16(3):354–9.
14. Timor-Tritsch IE, Monteagudo A, Cali G, El Refaey H, Kaelin Agten A, Arslan AA. Easy sonographic differential diagnosis between intrauterine pregnancy and cesarean delivery scar pregnancy in the early first trimester. *Am J Obstet Gynecol.* 2016;215(2):e2251–7.
15. Nyberg DA, Mack LA, Jeffrey RB Jr, Laing FC. Endovaginal sonographic evaluation of ectopic pregnancy: a prospective study. *AJR Am J Roentgenol.* 1987;149(6):1181–6.
16. Casikar I, Reid S, Condous G. Ectopic pregnancy: Ultrasound diagnosis in modern management. *Clin Obstet Gynecol.* 2012;55(2):402–9.
17. Comstock C, Huston K, Lee W. The ultrasonographic appearance of ovarian ectopic pregnancies. *Obstet Gynecol.* 2005;105(1):42–5.
18. Bouyer J, Coste J, Shojaei T, Pouly JL, Fernandez H, Gerbaud L, et al. Risk factors for ectopic pregnancy: a comprehensive analysis based on a large case-control, population-based study in France. *Am J Epidemiol.* 2003;157(3):185–94.

19. Lee MH, Im SY, Kim MK, Shin SY, Park WI. Comparison of laparoscopic cornual resection and Cornuotomy for interstitial pregnancy. *J Minim Invasive Gynecol.* 2017;24(3):397–401.

Publisher's Note

Springer Nature remains neutral with regard to jurisdictional claims in published maps and institutional affiliations.